



# **A Slow Flow Oral Vascular Malformation Managed by Sclerotherapy (3% Sodium Tetradecyl Sulfate) and Diode Laser (980nm): A Case Report**

**Sabina Chhaju <sup>a</sup>, Vedant Prasad <sup>b++</sup>,  
Ashutosh Kumar Rai <sup>b++</sup>, Himali Pun <sup>a</sup>, Bismita Karki <sup>c</sup>  
and Peeyush Shivhare <sup>d#\*</sup>**

<sup>a</sup> Department of Dentistry, Nobel Medical College Teaching Hospital, Biratnagar, Nepal.

<sup>b</sup> Faculty of Dental Sciences, IMS, BHU, Varanasi, India.

<sup>c</sup> Department of Dentistry, Kantipur Dental College, Nepal.

<sup>d</sup> Baba Kinaram Autonomous State Medical College, Chandauli, (U.P.), India.

## **Authors' contributions**

*This work was carried out in collaboration among all authors. All authors read and approved the final manuscript.*

## **Article Information**

DOI: <https://doi.org/10.9734/ijrrd/2025/v8i1202>

### **Open Peer Review History:**

This journal follows the Advanced Open Peer Review policy. Identity of the Reviewers, Editor(s) and additional Reviewers, peer review comments, different versions of the manuscript, comments of the editors, etc are available here: <https://www.sdiarticle5.com/review-history/129140>

**Case Report**

**Received: 30/10/2024**

**Accepted: 01/01/2025**

**Published: 07/01/2025**

<sup>++</sup> Intern;

<sup>#</sup> Associate Professor and Head;

<sup>\*</sup>Corresponding author: Email: [drshivharepeeyush3@gmail.com](mailto:drshivharepeeyush3@gmail.com);

**Cite as:** Chhaju, Sabina, Vedant Prasad, Ashutosh Kumar Rai, Himali Pun, Bismita Karki, and Peeyush Shivhare. 2025. "A Slow Flow Oral Vascular Malformation Managed by Sclerotherapy (3% Sodium Tetradecyl Sulfate) and Diode Laser (980nm): A Case Report". *International Journal of Research and Reports in Dentistry* 8 (1):9-15. <https://doi.org/10.9734/ijrrd/2025/v8i1202>.

## ABSTRACT

Vascular anomalies or lesions consist of wide spectrum of congenital lesions of vascular origin. Broadly, it is classified into proliferative vascular tumors and nonproliferative vascular malformations. Based on the hemodynamic flow, vascular malformations can be classified as high (arteriovenous malformation and arteriovenous fistulas) and low-flow lesions (capillary, venous, lymphatic). Venous malformations commonly seen in the oral region affecting lips, tongue, buccal mucosa, and palate, appear as bluish to deep purple, soft, compressible, pulsatile lesion. Various treatment modalities such as sclerotherapy, surgical resection, laser therapy, cryotherapy, medical therapy can be utilized to manage low-flow vascular malformations. Sclerotherapy and laser are both effective in the management of vascular malformation. We are reporting a case of low-flow vascular malformation managed by sclerotherapy with 3% sodium tetradecyl sulphate followed by diode laser 980nm. No case has been published in which sclerotherapy and laser has been utilized in the same lesion, making this case unique.

*Keywords: Vascular anomalies; venous malformations; sclerotherapy; cryotherapy.*

## 1. INTRODUCTION

Vascular anomalies or lesions consist of wide spectrum of congenital lesions of vascular origin (Shivhare & Parihar, 2021). Broadly, it is classified into proliferative vascular tumors and nonproliferative vascular malformations (Wassef et al., 2021). In contrast to vascular tumour, vascular malformations (VM) are structural anomalies of blood vessels without endothelial proliferation (Shivhare & Parihar, 2021). VMs are usually present at birth but manifest at later age due to precipitating factors like localised trauma. VMs classified into simple (capillary, venous, lymphatic arteriovenous malformation, arteriovenous fistulas) and combined (combination of two or more simple VMs) (Shivhare & Parihar, 2021; Wassef et al., 2021; Das et al., 2023). Based on the hemodynamic flow characteristics, VMs can also be classified as high (arteriovenous malformation and arteriovenous fistulas) and low-flow lesions (capillary, venous, lymphatic) (Shivhare & Parihar, 2021; Wassef et al., 2021; Das et al., 2023). These lesions can occur anywhere in the body including oral cavity. VMs are commonly found in the oral region, which encompasses the lips, tongue, buccal mucosa, and palate (Shivhare & Parihar, 2021). Capillary malformation, sometimes termed as port-wine stain, manifests as a large patch of purple or dark red (Wassef et al., 2021). Venous malformation appears as bluish to deep purple, soft, compressible, pulsatile lesion. Clinically, these lesions blanched on pressure i.e. positive diascopy test (Shivhare & Parihar, 2021; Wassef et al., 2021). Before beginning any intervention, the flow of these lesions must be confirmed with imaging modalities such as Doppler ultrasound and MRI angiography (Das et al., 2023;

Brahmbhatt et al., 2020). Various treatment modalities such as sclerotherapy, surgical resection, laser therapy, cryotherapy, medical therapy can be utilized to manage low-flow vascular malformations (Shivhare et al., 2022). Factors like type, location, depth, and progression of the lesion determine the treatment method. Surgical resection usually has various potential limitations such as bleeding, incomplete resection, esthetic concern, scarring and functional impairment. Considering these limitations, alternative treatment modalities such as sclerotherapy, laser treatment are nowadays preferred (Shivhare et al., 2022; Shivhare et al., 2019).

Sclerotherapy involves injecting a sclerosant solution intralesionally, which causes tissue irritation, inflammation, endothelial damage with minimal thrombosis and tissue necrosis. These events eventually lead to fibrosis and tissue contracture, resulting in the disappearance of the lesion (Shivhare et al., 2019). There are different types of sclerosing agents that can be categorized by the chemical properties and method of action (Shivhare et al., 2019; Ramakrishnan et al., 2021).

Bleomycin, polidocanol (POL), absolute ethanol and sodium tetradecyl sulfate (STS) are the most commonly used sclerosants for oral and maxillofacial vascular lesions (Shivhare & Parihar, 2021; Ramakrishnan et al., 2021). Sodium 1-isobutyl-4-ethyl octyl sulfate (STS) is manufactured synthetically and commonly used as synthetic surfactant (soap) (Shivhare et al., 2019). STS has shown its efficacy in the management of various oral lesions such as vascular malformation, pyogenic granuloma,

lymphangioma, mucocele and Ranula (Shivhare et al., 2019; Subramanyam & Shivhare, 2021).

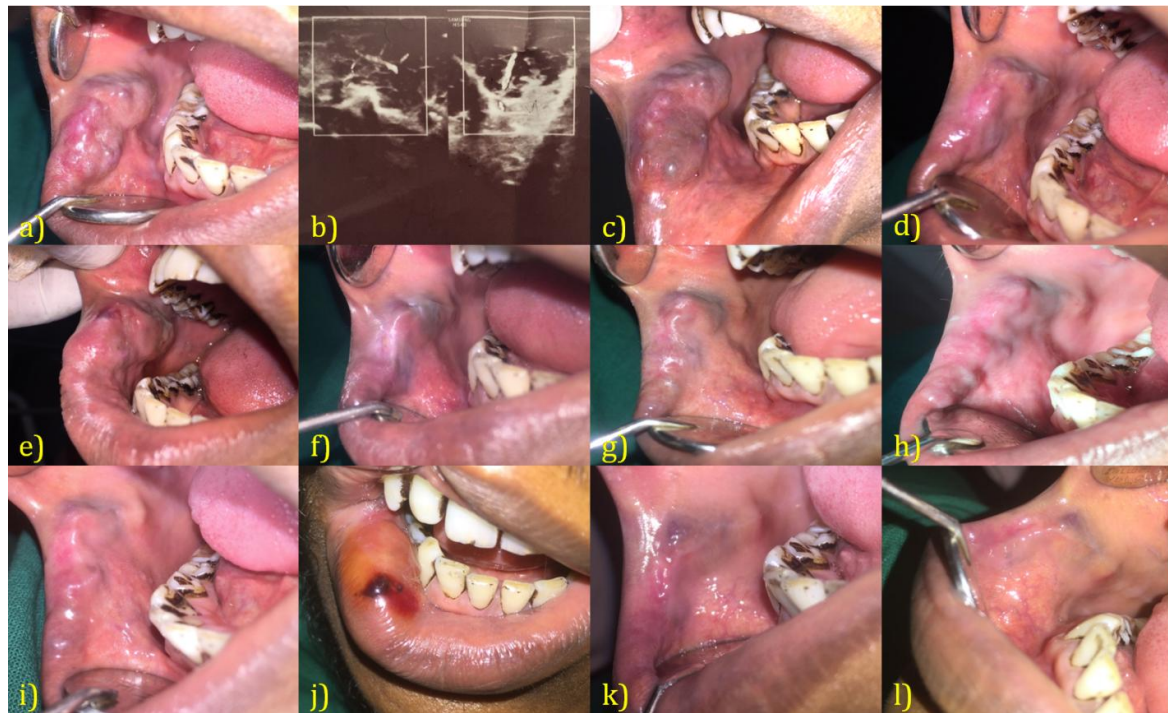
Laser machine emits electromagnetic radiation through optical amplification, following the principle of spontaneous emission (Shivhare et al., 2022). The laser is absorbed selectively by hemoglobin and it also generates heat within the tissue, causing blood to coagulate, which is known as photocoagulation (Shivhare et al., 2022; Angiero et al., 2008). Laser is utilized in managing VMs by laser excision, Transmucosal thermocoagulation and/or intralesional photocoagulation (ILP) (Romeo et al., 2013; Miyazaki et al., 2009). Commonly used lasers in the management of vascular malformations include diode laser, potassium–titanium phosphate (KTP) laser, neodymium–yttrium–aluminum–garnet (Nd: YAG) laser, pulsed dye laser, argon laser, and carbon dioxide (CO<sub>2</sub>) laser (Shivhare et al., 2022).

We are presenting a case of large venous malformation of buccal mucosa, successfully managed with sclerotherapy (3% Sodium tetradecyl sulphate) followed by transmucosal

thermocoagulation with diode laser therapy (980nm).

## 2. CASE PRESENTATION

A 24 year male patient reported to our department of dentistry, with complaint of bluish swelling of right inner surface of cheek since 1 year. The size was gradually increased until it reached its current size, and it is slowly increasing in size. On examination, multilobulated bluish purple swelling was identified in relation to right buccal mucosa measuring about 3.5 (Anteroposteriorly) x2cm (Superoinferiorly) in size, extending anteroposteriorly from retro-commissural region to 3.5cm posteriorly. Superoinferiorly extends from the 0.5cm superior to occlusal plane to 1.5cm inferiorly (Fig. 1a). It was soft in consistency, nontender with feebly pulsatile. The lesion blanched on pressure (Positive diascopy test). Clinically, vascular malformation was given as provisional diagnosis. On Doppler ultrasound, few vascular structures with venous pattern are seen within hypoechoic lesion suggestive of slow flow vascular malformation (Fig. 1b).

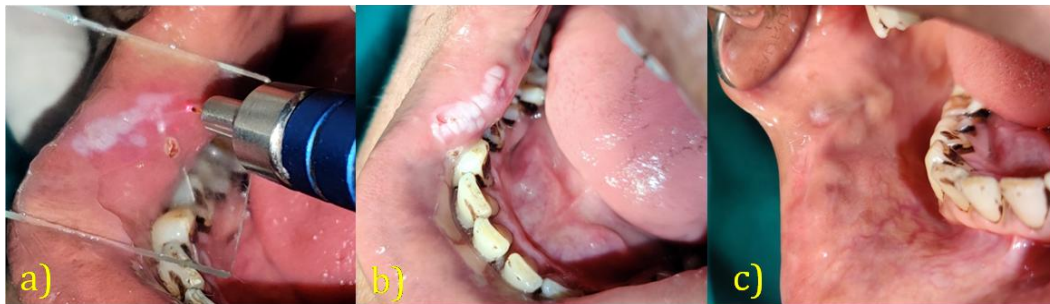

**Fig. 1. a) Presence of vascular malformation of right buccal mucosa. b) Doppler ultrasound suggestive of slow flow malformation c) The lesion turns dark blue soon after injection d) 20% reduction after 2 week e) post injection soon after second session f) 10 days after second session g) 20 days after second session h) 30 days after second session i) 40 days after second session j) third session of injection - Ecchymosis with local edema was detected k) 10 days after third session l) 21 days after third session**

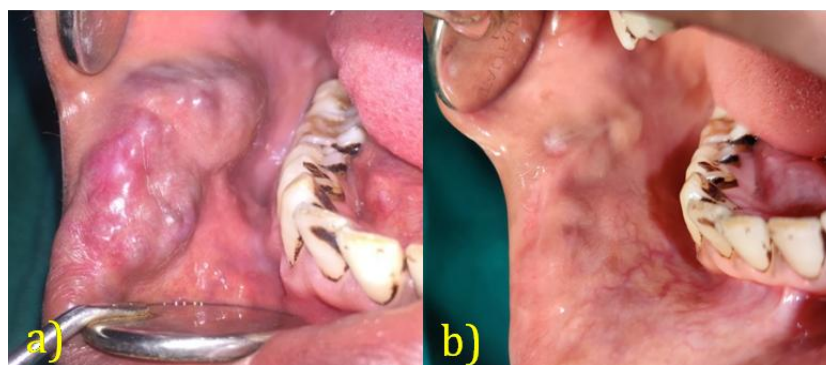
**Sclerotherapy with 3% Sodium Tetradecyl Sulfate:**

After radiographic confirmation, Sclerotherapy was planned with 3% Sodium Tetradecyl Sulfate. The surgical procedure and its potential complications were thoroughly explained, along with their consent. After applying the surface anesthesia with 15% xylocaine spray, the patient was given an intralesional injection of 3 % STS solution. Once the lesion was clinically confirmed with positive aspiration of blood, the sclerosing agent was injected intralesionally at multiple sites. Using an insulin syringe, the injection begins at the

periphery and then proceeds to the center of the lesion till the point of blanching. The lesion turns dark blue soon after injection (Fig. 1c). Postoperatively, antibiotics and analgesics were prescribed. The patient experienced severe pain (VAS score 8) without any other complications. The patient was recalled two weeks later and there was a 20% reduction in area (Fig. 1d). This injection was repeated with 0.2ml STS (Fig. 1e). The patient was reassessed every 10 days (Figs. 1e-1i). A small ulcerative lesion was noticed 10 days after the second injection, which eventually healed (Figs. 1f, 1g).



**Fig. 2. a) TTP was performed by keeping the laser tip at 2mm distance from the lesion with glass slide, to prevent accidental perforation b) Procedure was completed with whitening of the entire lesion c) Complete disappearance of the lesion was seen after 20 days of laser treatment**



**Fig. 3. Pre and Post Treatment – Complete disappearance of the lesion**

**Table 1. The parameters used for the diode laser device**

<b>Type of laser</b>	Diode laser (Ga-Al-As, DILAS, Germany; IndiLase, MEDSOL, Hosur, India)
<b>Emission mode</b>	Continuous mode with initiated tip
<b>Contact/noncontact mode</b>	Noncontact mode
<b>Delivery system</b>	400 µm, Polyamide coated Optical fiber
<b>Wavelength</b>	980-nm
<b>power</b>	2 watt
<b>Energy density</b>	1592.35 Jule/cm <sup>2</sup>
<b>Tip initiation</b>	Yes
<b>Voice confirmation</b>	Yes

After 2 months of the second injection, a 50% reduction was detected (Fig. 1i). Third session of injection was planned with 0.2ml. Soon after injection, ecchymosis with local edema was seen with moderate pain (VAS score 6) (Fig. 1j). The patient was assessed on 10<sup>th</sup> and 21<sup>st</sup> day after 3<sup>rd</sup> injection. 80 % reduction was detected (Fig. 1k.l). For residual lesion, transmucosal thermocoagulation with diode laser (980nm) was planned due to postoperative complications caused by sclerotherapy.

**Transmucosal thermocoagulation with diode laser (980nm):** After Perilesional infiltration of local anaesthetic (2% lignocaine without epinephrine) treatment was performed with 980-nm diode laser (Ga-Al-As, DILAS, Germany; IndiLase, MEDSOL, Hosur, India) using the parameters listed in Table 1. The laser tip was kept 2mm distance from the lesion with glass slide, to prevent accidental perforation (Fig. 2a). Irradiation was delivered in continuous and noncontact mode with initiated tip. The treatment progressed from the periphery to the central region with quick circular movements. To avoid deeper thermal damage, the tip was not held for long time at the same location. The laser site was also irrigated with cold physiological solution. The laser beam was moved to other areas, once the clinical sign of whitening was identified. The procedure was completed with whitening of the entire lesion along with 1-2 mm beyond the visible margins (Fig. 2b). We ensured complete aseptic conditions, with both the patient and operators wearing protective eyeglasses. Analgesics were prescribed postoperatively. We prescribed a topical antiseptic solution (i.e., Betadine 2%) for oral rinsing. Patient was asked to refrain from eating hard or hot foods for the first 3 days post-intervention. Complete disappearance of the lesion was seen after 20 days of laser treatment (Figs. 2c, 3). Only mild pain (VAS-02) was recognized as post-surgical complications in contrast to sclerotherapy. No recurrence was encountered in follow up period of 1.5year.

### 3. DISCUSSION

For oral lesions, Sclerotherapy and Laser therapy, both are proven to be a potent alternative to traditional surgical excision due to their various advantages (Shivhare et al., 2022; Shivhare et al., 2019). The advantages of sclerotherapy as described in various literatures are simple, easily available, negligible blood loss, comparatively safe, no requirement of local

anesthetic or postoperative dressing (Shivhare et al., 2019).

A retrospective study concluded that the 3% STS sclerotherapy is effective in the treatment of various oral lesions including vascular malformations (Shivhare et al., 2019). Considering patients with VM, complete response seen in 55.6%, good response in 22.2%, moderate response in 11.1% and mild response in 11.1% (Shivhare et al., 2019). The results of another study showed complete resolution in 28.57, good response in 35.7 %, moderate response in 14.28 %, mild response in 14.28 % and no response in 7.14 % in VMs patients treated with intralesional injections of 3% STS (Alakailly et al., 2015).

Transmucosal thermocoagulation involves the temperature (heat) induced coagulation through the mucosa. While passing through tissues, the lasers beam absorbed by hemoglobin and also produce heat that causes coagulation, thus termed as "photocoagulation". Laser tip is kept at a distance of 2-3mm (noncontact mode) (Angiero et al., 2008). In contrast to this, intralesional photocoagulation (ILP) includes insertion of tip directly inside the lesion. Thus the energy is released directly within the lesion (Miyazaki et al., 2009). The chances of bleeding and scarring is high in ILP (Bacci et al., 2018), thus we preferred TTP in our case.

In general, the advantages of laser therapy are increased patient comfort, bloodless dry operating field, bactericidal effect, lesser post-operative pain, lesser chances of scarring, lesser post-operative swelling and minimal local anaesthesia and lesser recurrence rate than scalpel surgery (Aldelaimi & Khalil, 2015; Aldelaimi et al., 2019). Diode laser has an additional biostimulatory effect compared to other laser, which increases growth promoting tissue (Shivhare et al., 2022).

Various literatures favored "Transmucosal thermocoagulation" for the management of low flow vascular malformation (Shivhare et al., 2022; Bacci et al., 2018; Sarfi et al., 2021). A study compared the efficacy of sclerotherapy and diode laser (TTP) in the management of low flow vascular malformation. Sclerotherapy group showed complete response in 90% and good response in 10% cases while laser group showed complete response in 80% and good response in 20% cases. Both modalities were effective in reducing size of the lesion although

recurrences were observed more on laser group (Shivhare et al., 2022).

Compared to laser treatment, Intralesional sclerotherapy may present with postoperative complications such as pain, ulceration, edema, Nicolau syndrome (ecchymosis followed by tissue necrosis) and chances of anaphylaxis (Shivhare et al., 2019; Ramakrishnan et al., 2021; Subramanyam & Shivhare, 2021). Postoperative complications like postoperative pain, edema was more on sclerotherapy group compared to laser group in a study. Sclerotherapy showed severe pain (VAS score-7-10) in 70 % cases, while most of the cases in laser group had only mild pain (VAS Score-1-4) (Shivhare et al., 2022). Our case was in accordance of this study, our case also showed severe pain with edema with sclerotherapy compared to mild pain with laser.

#### 4. CONCLUSION

Sclerotherapy and laser are both effective in the management of vascular malformation. Both can be used as a single treatment modality. If the lesion is extensive and if 2-3 injections cannot give complete elimination sclerotherapy, it can be followed by laser treatment similar to our case. No case has been published in which sclerotherapy and laser has been utilized in the same lesion, making this case unique. Further publication is required to make this technique more valid.

#### CONSENT

As per international standards or university standards, patient(s) written consent has been collected and preserved by the author(s).

#### ETHICAL APPROVAL

It is not applicable.

#### DISCLAIMER (ARTIFICIAL INTELLIGENCE)

Author(s) hereby declare that NO generative AI technologies such as Large Language Models (ChatGPT, COPILOT, etc) and text-to-image generators have been used during writing or editing of this manuscript.

#### COMPETING INTERESTS

Authors have declared that no competing interests exist.

#### REFERENCES

- Alakailly, X., Kummoona, R., Quereshy, F. A., Baur, D. A., & González, A. E. (2015). The use of sodium tetradecyl sulphate for the treatment of venous malformations of the head and neck. *Journal of Maxillofacial and Oral Surgery*, 14(2), 332-338.
- Aldelaimi, A. A., Ahmed, R. F., Enezei, H. H., & Aldelaimi, T. N. (2019). Gummy smile esthetic correction with 940 nm diode laser. *International Medical Journal*, 26(6), 513-515.
- Aldelaimi, T. N., & Khalil, A. A. (2015). Clinical application of diode laser (980 nm) in maxillofacial surgical procedures. *Journal of Craniofacial Surgery*, 26(4), 1220-1223.
- Angiero, F., Benedicenti, S., Romanos, G. E., & Crippa, R. (2008). Treatment of hemangioma of the head and neck with diode laser and forced dehydration with induced photocoagulation. *Photomedicine and Laser Surgery*, 26(2), 113-118.
- Bacci, C., Sacchetto, L., Zanette, G., & Sivoletta, S. (2018). Diode laser to treat small oral vascular malformations: A prospective case series study. *Lasers in Surgery and Medicine*, 50(2), 111-116.
- Brahmbhatt, A. N., Skalski, K. A., & Bhatt, A. A. (2020). Vascular lesions of the head and neck: An update on classification and imaging review. *Insights into Imaging*, 11(1), 19.
- Das, A., Goyal, A., Sangwan, A., Bhalla, A. S., Kumar, A., Kandasamy, D., et al. (2023). Vascular anomalies: Nomenclature, classification, and imaging algorithms. *Acta Radiologica*, 64(2), 837-849.
- Miyazaki, H., Kato, J., Watanabe, H., Harada, H., Kakizaki, H., Tetsumura, A., et al. (2009, February). Intralesional laser treatment of voluminous vascular lesions in the oral cavity. *Oral Surgery, Oral Medicine, Oral Pathology, Oral Radiology and Endodontics*, 107(2), 164-172.
- Ramakrishnan, K., Palanivel, I., Narayanan, V., Chandran, S., & Gurram, P. (2021). Management of vascular malformations in the oral and maxillofacial region: A systematic review. *Journal of Stomatology, Oral and Maxillofacial Surgery*, 122(6), 588-599.
- Romeo, U., Del Vecchio, A., Russo, C., Gaspare, P., Gaimari, G., Dominguez, J. A., et al. (2013). Laser treatment of 13 benign oral vascular lesions by three different surgical

- techniques. *Medicina Oral, Patología Oral y Cirugía Bucal*, 18(2), e279-e284.
- Sarfi, D., Adnane, S., Haitami, S., & Ben Yahya, I. (2021). Diode laser photocoagulation of intraoral (and perioral) venous malformations: Case series. *International Journal of Surgical Case Reports*, 88, 106436.
- Shivhare, P., & Parihar, A. (2021). Pigmented lesions. In P. Shivhare & A. Parihar (Eds.), *Textbook of Oral Medicine and Radiology* (2nd ed., pp. 329-362). Paras Publisher.
- Shivhare, P., Haidry, N., Sah, N., Kumar, A., Gupta, A., et al. (2022, September 17). Comparative evaluation of efficacy and safety of the diode laser (980 nm) and sclerotherapy for the treatment of oral pyogenic granuloma. *International Journal of Dentistry*, 2022, 8269221.
- Shivhare, P., Haidry, N., Sah, N., Kumar, A., Gupta, A., Singh, A., et al. (2022). Comparative evaluation of efficacy and safety of the diode laser (980 nm) and sclerotherapy in the treatment of oral vascular malformations. *International Journal of Vascular Medicine*, 2022, 2785859.
- Shivhare, P., Singh, V., & Singh, A. (2019). Use of sodium tetradecyl sulphate for the treatment of oral lesions. *JCMS Nepal*, 15(4), 276-280.
- Subramanyam, S., & Shivhare, P. (2021). Pyogenic granuloma—A simple treatment approach with sclerotherapy. *Acta Scientific Dental Sciences*, 5(3), 111-114.
- Wassef, M., Borsik, M., Cerceau, P., Faucon, B., Laurian, C., Le Clerc, N., et al. (2021). Classification of vascular tumours and vascular malformations. Contribution of the ISSVA 2014/2018 classification. *Annals of Pathology*, 41(1), 58-70.

**Disclaimer/Publisher's Note:** The statements, opinions and data contained in all publications are solely those of the individual author(s) and contributor(s) and not of the publisher and/or the editor(s). This publisher and/or the editor(s) disclaim responsibility for any injury to people or property resulting from any ideas, methods, instructions or products referred to in the content.

© Copyright (2025): Author(s). The licensee is the journal publisher. This is an Open Access article distributed under the terms of the Creative Commons Attribution License (<http://creativecommons.org/licenses/by/4.0>), which permits unrestricted use, distribution, and reproduction in any medium, provided the original work is properly cited.

Peer-review history:

The peer review history for this paper can be accessed here:  
<https://www.sdiarticle5.com/review-history/129140>