

# Case Report

## RABSON-MENDENHALL SYNDROME: A CASE REPORT

**ALAEI Mohammad Reza MD<sup>1</sup> ,  
MIRJAVADI Seyed Alireza MD<sup>2</sup> ,  
SHIARI Reza MD,Ph.D<sup>3</sup>**

1. Assistant Professor of Pediatric Endocrinology, Shahid Beheshti University of Medical Sciences, Tehran, Iran
2. Resident of Pediatric, Shahid Beheshti University of Medical Sciences, Tehran, Iran
3. Assistant Professor of Pediatric Rheumatology, Shahid Beheshti University of Medical Sciences, Tehran, Iran

Corresponding Author:  
Alaei MR.MD  
Mofid Children's Hospital,  
Tehran, Iran  
Tel: +98 21 22227033  
Fax: +98 21 22227033  
Email: alae2003@yahoo.com

Received: 31-May- 2010  
Last Revised: 7-June- 2010  
Accepted: 16-June- 2010

### Abstract

Rabson-Mendenhall syndrome is a rare genetic disorder characterized by growth retardation, dysmorphisms, lack of subcutaneous fat, acanthosis nigricans, enlarged genitalia, hirsutism, dysplastic dentition, coarse facial features, paradoxical fasting hypoglycemia, postprandial hyperglycemia, extreme hyperinsulinemia and pineal hyperplasia. Herein, we described a 10-year-old girl with physical features of the Rabson-Mendenhall syndrome that was presented with polyuria. To our knowledge, this is the first report of the Rabson-Mendenhall syndrome from Iran.

**Keywords:** Diabetes, Hirsutism, Insulin resistance, Clitoromegaly

### Introduction

Rabson-Mendenhall syndrome (RMS) is a rare genetic disorder that was first described by Rabson et al in 1956 (1). It is characterized by growth retardation, dysmorphisms, lack of subcutaneous fat, acanthosis nigricans, enlarged genitalia, hirsutism, dysplastic dentition, coarse facial features, paradoxical fasting hypoglycemia, postprandial hyperglycemia, extreme hyperinsulinemia, pineal hyperplasia, severe insulin resistance and hyperinsulinemia (1, 2).

Severe insulin resistance is caused by genetic defects of the insulin receptor gene (Type A syndrome, Leprechaunism and Rabson-Mendenhall syndrome) or by the presence of circulating auto-antibodies that disrupt the normal functions of the insulin receptor (Type B syndrome) (3, 4). RMS differs from leprechaunism in the presence of premature and dysplastic dentition (which is sometimes observed at birth), coarse facial features, and pineal hyperplasia (4, 5). These patients will ultimately develop severe insulin-resistant diabetes requiring very large doses of insulin to achieve normoglycaemia. However, the diagnosis now encompasses both teenage and adolescent males and females who are not obese but have severe insulin resistance and acanthosis nigricans in the absence of insulin receptor autoantibodies (5-7). Herein, we presented a 10-year-old girl with clinical features of the Rabson-Mendenhall syndrome that was presented with polyuria and medullary nephrocalcinosis. To our knowledge, this is the first report of the Rabson-Mendenhall syndrome from Iran.

### Case report

A 10-year-old Iranian girl presented to our department with a 2-year history of polyuria and polydipsia accompanied by a mild weight loss, malaise and mental retardation. Her physical examination revealed generalized skin hyperpigmentation (black) and coarse facies including a prominent orbital ridge, macroglossia, thickened lips, a

depressed nasal bridge, (acromegaloid ) and a dry skin with a creased, dark and velvety appearance, especially on her nape of the neck, axilla, groin and sacral region (Fig 1). She had large hands and fingers and a very prominent large clitoris (clitoromegaly) (Fig 2).

Her laboratory test results were as follows:

White blood cell count:  $8 \times 10^3/\text{mm}^3$  (neutrophils 42%, lymphocytes 51%, monocytes 4%), red blood cells count:  $424 \times 10^4/\text{mm}^3$ , platelets count:  $310 \times 10^3/\text{mm}^3$ , hemoglobin 13.8 g/dL, hematocrit: 38.1%, erythrocyte sedimentation rate: 23 mm/1<sup>st</sup> hr, Na: 135 mg/dl, K: 3.6 mg/dl, Ca: 9.7 mg/dl, blood sugar: 655 mg/dl (repeated: 435 mg/dl), aspartate aminotransferase: 38 U/L, alanine aminotransferase: 26 U/L, blood urea nitrogen: 17 mg/dL, creatinine: 0.5 mg/dL, total protein: 7.4 g/dL, serum albumin: 4.4g/dl, C-reactive protein: 17 mg/L (positive), triglycerides: 150 mg/dl, cholesterol: 86 mg/dl, partial thromboplastin time: 30 sec, prothrombin time: 16 second. Serum levels of cortisol, 17-hydroxyprogesteron, adrenocorticotropin hormone, testosterone, Dehydro Epiandrosterone (DHEA), thyroid function tests and her urine 17-ketosteroides were all within normal limits. Her fasting glucose to insulin ratio was 5.25 (FBS:105 mg/dl, serum insulin level: 20  $\mu\text{U}/\text{ml}$ ) which is a significant indicator of insulin resistance. Her urine analysis showed glucosuria (2<sup>+</sup>). Other evaluations including chest x ray, abdominal sonography, and cardiac echocardiography were normal.

According to her clinical findings and laboratory results, she was diagnosed with Rabson-mendenhall syndrome.

### Discussion

Rabson and Mendenhall reported three siblings with skeletal abnormalities and Insulin-resistant diabetes mellitus that also suffered from dental and skin abnormalities, abdominal distension, phallic enlargement, early dentition, coarse senile-looking facies, striking hirsutism, mental precocity, prognathism, thick fingernails, acanthosis nigricans, Insulin-resistant diabetes mellitus, ketoacidosis, intercurrent infections, pineal hyperplasia and ovarian tumor (1). Later in 1975, West et al. described siblings with similar clinical features (2). All these patients had generalized skin hyperpigmentation, coarse facies (a prominent orbital ridge, macroglossia, thickened lips, a depressed nasal

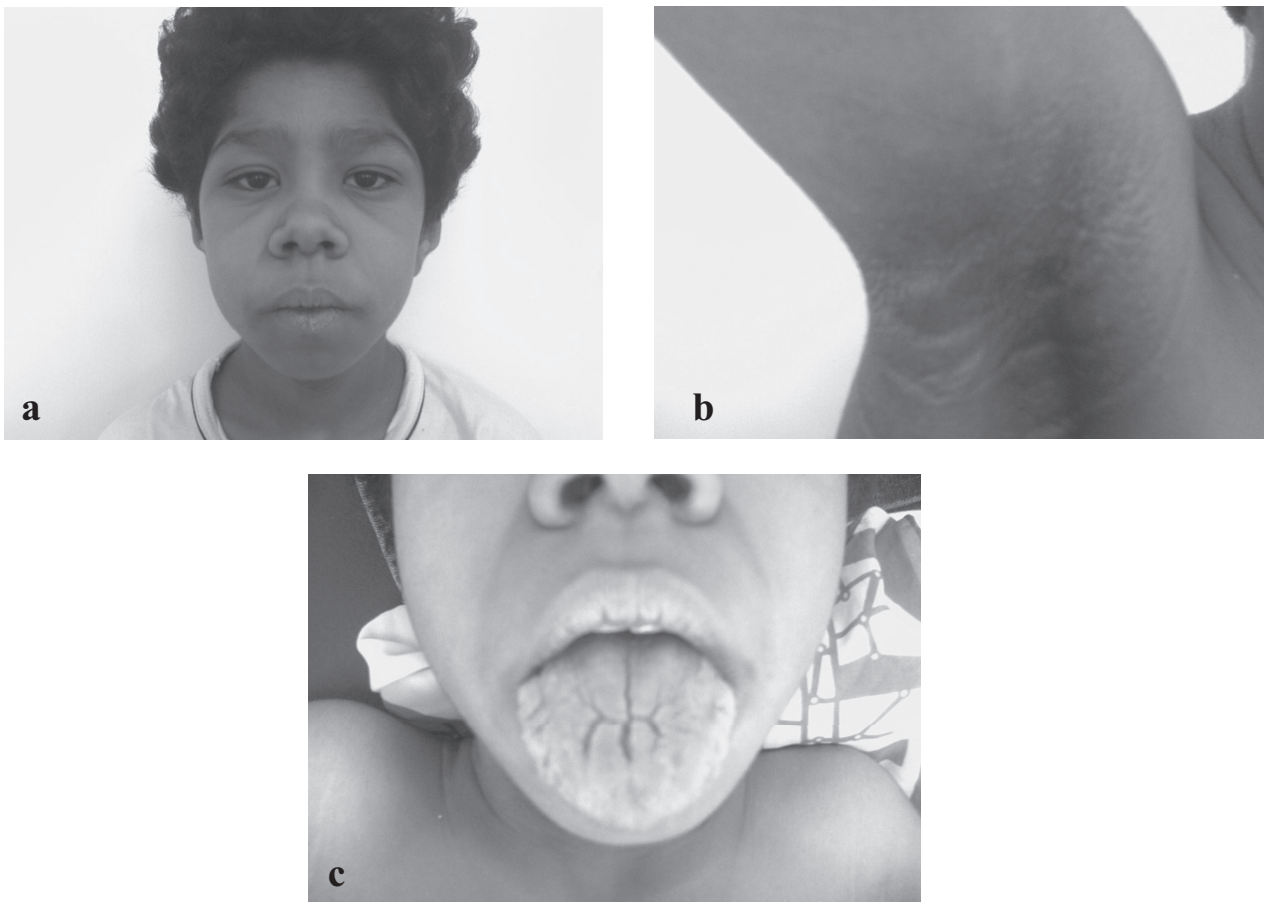
bridge) and a dry skin with a creased, dark and velvety appearance especially on nape of neck, axilla, groin and sacral region (1, 2).

The primary defect in RMS appears to be in the insulin receptors. The gene map locus is 19p13.2. (3-5). Leprechaunism and RMS are autosomal recessive conditions with abnormal alleles for insulin receptors (5, 6). Growth retardation, dysmorphisms, lack of subcutaneous fat, acanthosis nigricans, enlarged genitalia, hirsutism, paradoxical fasting hypoglycemia and postprandial hyperglycemia and extreme hyperinsulinemia is seen in both conditions (6, 7). Children with leprechaunism die in infancy, have severe manifestations, do not develop diabetic ketoacidosis and their major problem is fasting hypoglycemia (3, 6, 8, 11). Cells from most patients with leprechaunism have absent insulin binding. RMS differs from leprechaunism by being less severe and by the presence of premature and dysplastic dentition, coarse facial features, gingival hyperplasia, pineal hyperplasia, and survival beyond one year of age (6, 10). The mutations in the insulin receptor gene cause a spectrum of inherited insulin-resistance syndromes ranging from severe leprechaunism to Type A insulin resistance (usually evident after puberty). RMS has an intermediate phenotype with survival beyond one year but death usually before puberty (7-10). Patients with RMS develop severe and intractable ketoacidosis. There is a paradoxical fasting hypoglycemia and postprandial hyperglycemia early in life, followed by constant hyperglycemia (by four years of age) and constant ketoacidosis by six years of age. Although insulin levels are extremely elevated initially and then decrease with age, they remain higher than normal values (10, 11). The paradoxical fasting hypoglycemia is caused by inappropriately elevated insulin levels at the time of fasting, due to excessive production of insulin by the pancreas, coupled with the prolonged half-life of the hormone (11). Affected patients remain insensitive to exogenous insulin. Ketoacidosis has been shown to reverse when high doses of insulin are administered. The absence of postprandial hyperglycemia in our case was a surprising finding, which cannot be explained on the basis of our current understanding of the syndrome. Patients with RMS are treated with high doses of insulin and insulin-sensitizing drugs such as metformin and

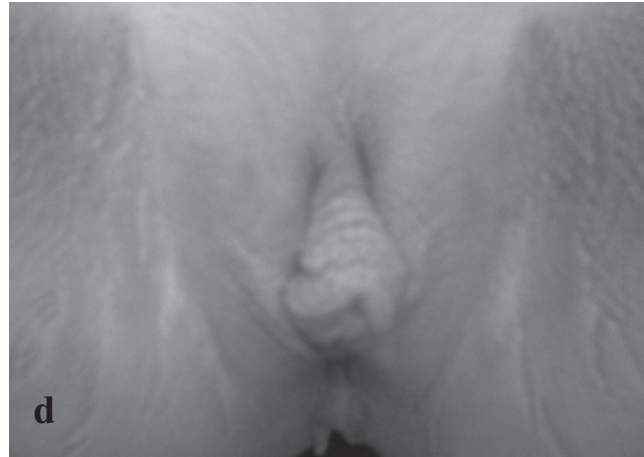glitazones (7, 8). Use of recombinant human growth hormone and recombinant human insulin-like growth factor-I has not been associated with encouraging results as far as growth is concerned (5, 9, 10). Leprechaunism and RMS should be considered as a continuous spectrum, in which the specific mutation and the degree of impairment of insulin action predict the survival, rather than the type of the syndrome. Extreme insulin resistance is observed in patients with leprechaunism and Rabson-Mendenhall syndrome. They are autosomal recessive conditions in which both alleles for the insulin receptor are abnormal and patients fail to respond to endogenous and exogenous insulin. Affected patients have dysmorphic features, lack of subcutaneous fat, acanthosis nigricans, enlargement of genitalia, hirsutism, paradoxical fasting hypoglycemia and postprandial hyperglycemia, and extremely elevated

levels of circulating insulin, up to 1000 times above normal. Children with leprechaunism usually die in the 1<sup>st</sup> year of life. They do not develop diabetic ketoacidosis, and although they have postprandial hyperglycemia, their major metabolic problem is fasting hypoglycemia (12). Renuka reported a 4.5-year-old girl with dental complications whereas our case had no dental anomalies (13).

In Conclusion, the phenotypic characteristics of Rabson-mendenhall syndrome are well identified which in most cases, favors the clinical diagnosis. The Rabson - mendenhall syndrome is a very unusual syndrome that illustrates the importance of the severe insulin resistance. A better understanding of this syndrome may open new horizons in the research of more prevalent diseases such as diabetes mellitus and insulin resistance.



**Fig 1.** (a) Black and coarse facies, prominent orbital ridge, acromegaloid, (b) Generalized skin hyperpigmentation and a dry skin with a creased, dark and velvety appearance, especially on axilla, groin and sacral region, (c) Macroglossia and thickened lips



**Fig 2.** Clitoromegaly of the same patient

### Reference

1. Rabson S, Mendenhall E .Familial hypertrophy of pineal body, hyperplasia of adrenal cortex and diabetes mellitus; report of 3 cases. *Am J Clin Pathol* 1956;26 (3): 283–90.
2. West R J, Lloyd JK, Turner WML. Familial insulin-resistant diabetes, multiple somatic anomalies, and pineal hyperplasia. *Arch Child Dis* 1975; 50: 703-708,
3. Araki S. Syndromes of severe insulin resistance. *Nippon Rinsho* 1999;57:617-21.
4. Longo nicola, Yuhune wang. Progressive Decline in Insulin Levels in Rabson- Mendenhall Syndrome. *The Journal of Clinical Endocrinology & Metabolism* 1999;84(8): 2623-2624.
5. Longo N, Wang Y, Smith SA. Genotype-phenotype correlation in inherited severe insulin resistance. *Human Mol Genet* 2002;11:1465-75.
6. Mantzoros CS & Flier JS. Insulin resistance: the clinical spectrum. *Advances in Endocrinology and Metabolism* 1995; 6 :193-232.
7. Fowlkes JL, Bunn RC, Coleman HN, Hall B, Reid MC, Thrailkill KM. Severe deficiencies of IGF-I, IGF-II, IGFBP-3, ALS and paradoxically high-normal bone mass in a child with insulin-resistance syndrome (Rabson-Mendenhall type). *Growth Hormone & IGF Research* 2007; 17:399-407.
8. Davis A, Yarasheski KE, White NH, Canter C, Marshall B. Defective insulin receptors in Rabson-Mendenhall syndrome cause complete peripheral insulin resistance but minimal hepatic insulin response mains. *Pediatric Diabetes* 2000; 1: 66-73.
9. Longo N, Singh R, Griffin LD, Langley SD, Parks JS, Elsas LJ. Impaired growth in Rabson-Mendenhall syndrome: lack of effect of growth hormone and insulin-like growth factor-I. *J Clin Endocrinol Metab* 1994;79 : 799-805.
10. Rabson-Mendenhall syndrome. [Online Mendelian Inheritance in Man (OMIM)]. Johns Hopkins University. 1986 April [cited 1986 June 4]; Available from: URL: <http://www.ncbi.nlm.nih.gov/omim>.
11. Longo N, Singh R, Elsas LJ. Decreased half-life of insulin-like growth factor I in Rabson-Mendenhall syndrome. *J Inherit Metab Dis* 2001;24:546-50.
12. Musso C, Cochran E. Clinical course of genetic diseases of the insulin receptor (Type A and Rabson-Mendenhall syndromes): A 30-year prospective. *Medicine* 2004;83:209-22.
13. Renuka J. Bathi. Sameena Parveen. Rabson-Mendenhall syndrome: two case reports and a brief review of the literature. *Odontology* 2010;98:89-96